

**Patient Information**

**Patient ID:** PS-MAY-2019  
**Patient Name:** Paula Smith  
**Date of Birth:** 21-Jan-1980  
**Gender:** Female  
**Submission Date:** 2019-May-03 10:54

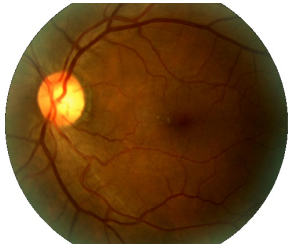
**General Information**

**Referring Location:** Eyenuk Inc  
**Referring Provider:** Dr. Michael Jones  
**Encounter ID:** 01  
**EyeArt Control ID:** 124054  
**Dilation Status:** Non Dilated

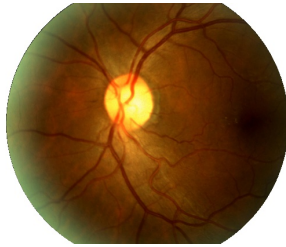**Diabetic Retinopathy Screening Summary**

**Screening Result:** Positive for vision threatening diabetic retinopathy.

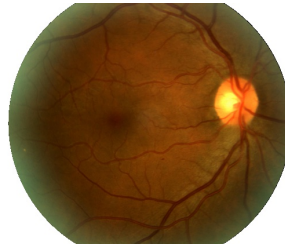
**Details:** Signs of Moderate NPDR [2.7] with macular edema detected



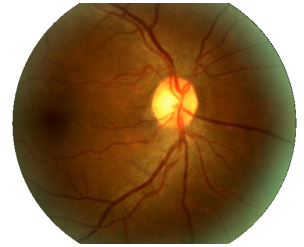Macula Centered [OS]



ONH Centered [OS]



Macula Centered [OD]



ONH Centered [OD]

\*Do not use the above thumbnail images for diagnostic purposes.

**ICD-10 Diagnosis Codes**

**E11.331** Type 2 diabetes mellitus with moderate nonproliferative diabetic retinopathy with macular edema

**Plan and Recommendations**

Immediate referral to ophthalmologist for evaluation of vision threatening diabetic retinopathy.

As per ADA recommendations, emphasize the importance of controlling blood sugar, cholesterol and blood pressure as well the importance of routine follow-up with an ophthalmologist regardless of whether visual symptoms are present or absent.

**Comments**

N/A

Report Date: 2019-May-03 10:55