

Patient Information

Patient ID: 1234567
Patient Name: Will Dallman
Date of Birth: 16-Jan-1900
Gender: Male
Submission Date: 2019-Oct-30 11:14

General Information

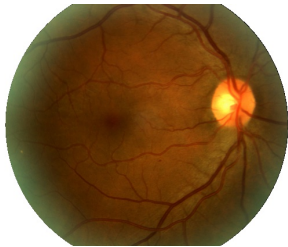Referring Location: Eyenuk
Referring Provider: Mr. Alejandro Quiñones
Encounter ID: 01
EyeArt Control ID: 141005
Dilation Status: Non Dilated

Diabetic Retinopathy Screening Summary

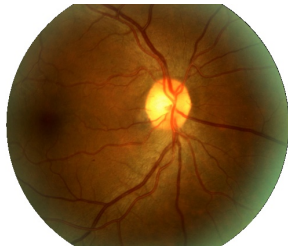
Screening Result: Positive for vision threatening diabetic retinopathy.

Right Eye: Signs of Moderate NPDR [2.3] without macular edema detected

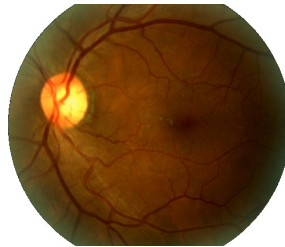
Left Eye: Signs of Moderate NPDR [2.9] with macular edema detected



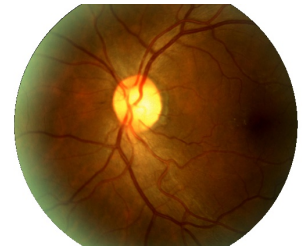
Macula Centered



ONH Centered



Macula Centered



ONH Centered

*Do not use the above thumbnail images for diagnostic purposes.

ICD-10 Diagnosis Codes

- E10.3391** Type 1 diabetes mellitus with moderate nonproliferative diabetic retinopathy without macular edema, right eye
- E10.3312** Type 1 diabetes mellitus with moderate nonproliferative diabetic retinopathy with macular edema, left eye

Plan and Recommendations

Immediate referral to ophthalmologist for evaluation of vision threatening diabetic retinopathy.

As per ADA recommendations, emphasize the importance of controlling blood sugar, cholesterol and blood pressure as well the importance of routine follow-up with an ophthalmologist regardless of whether visual symptoms are present or absent.

Comments

Left Eye: None
Right Eye: None

Report Date: 2019-Oct-30 11:15