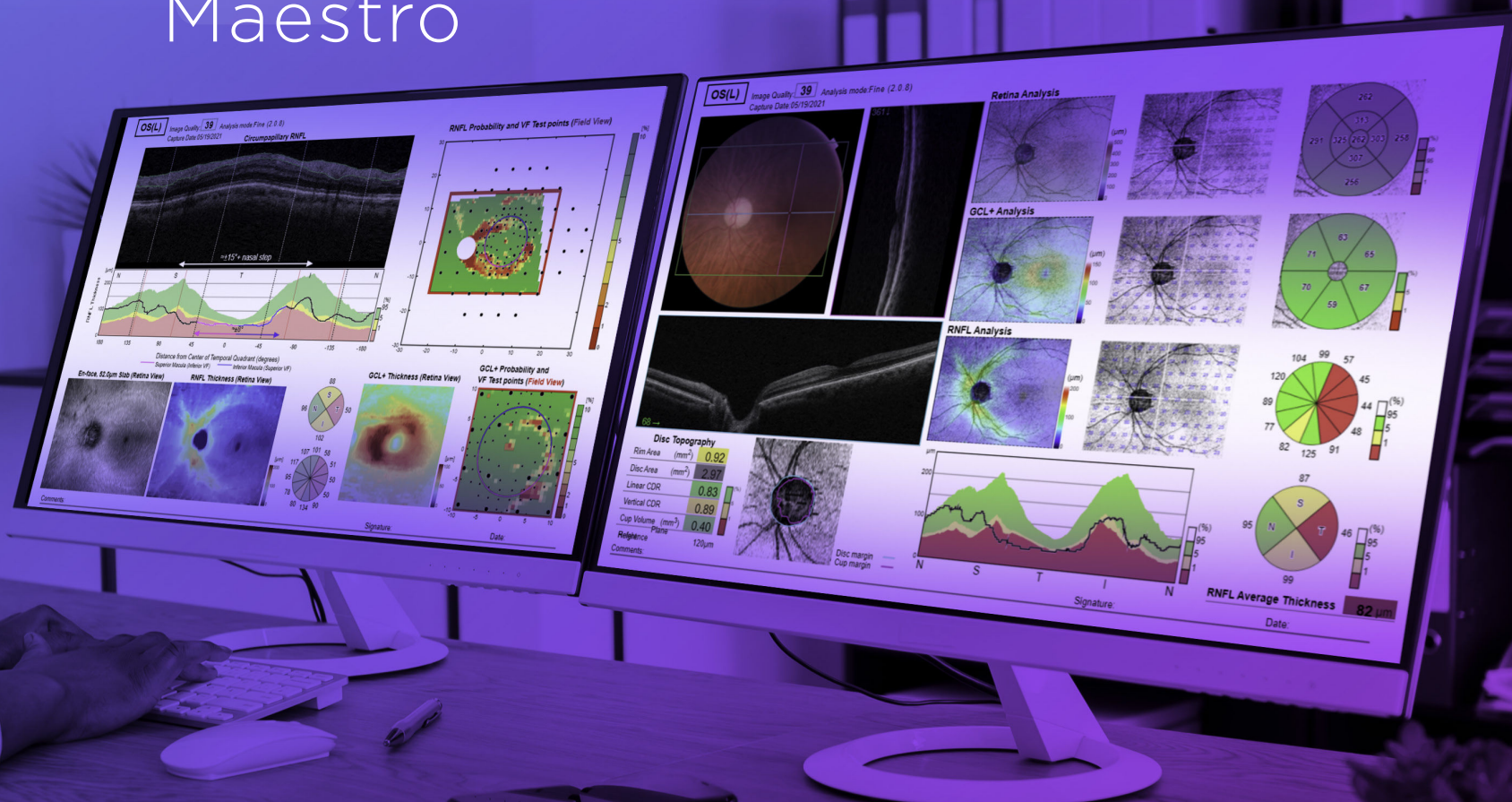


Topcon OCT Report Guide

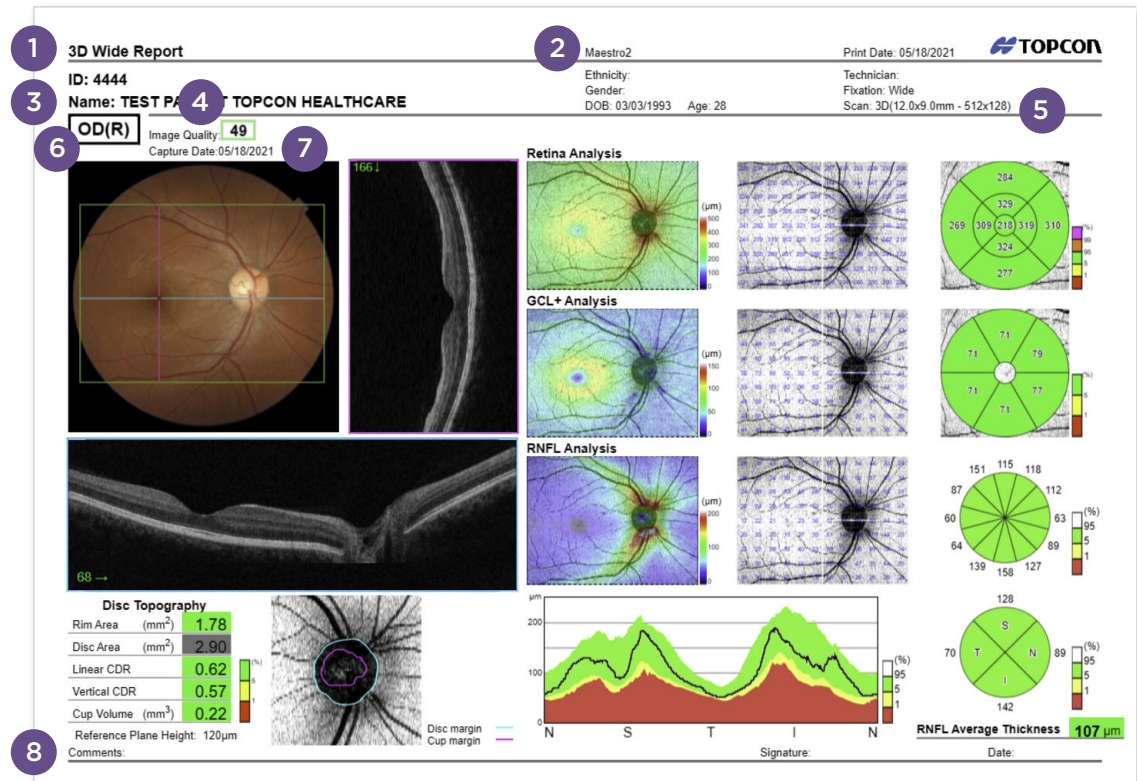
Maestro



Reports (click on Report Title)

- ☐ Report Elements at a Glance **P2**
- ☒ 3D Wide Report (12x9 mm) **P3**
- ☒ 3D Wide Glaucoma Report **P4**
- ☒ 3D Wide Glaucoma Report with Visual Field Test Points (Hood Report) **P5**
- ☒ 3D Wide Trend Analysis (OU) **P6**
- ☒ 3D Disc Report with Topography **P7**
- ☒ 3D Disc Report (OU) with Topography **P8**
- ☒ 3D Disc Trend Analysis (OU) **P9**
- ☒ Anterior Line Report/Anterior Radial Report/ Anterior Line Report (Angle) **P10**
- ☒ 3D Macula Report **P11**
- ☒ 3D Macula Report (OU) – Retina Analysis **P12**
- ☒ 3D Macula Report (OU) – GCL Analysis **P13**
- ☒ Compare Report (Change Analysis) **P14**
- ☒ Line Report/5 Line Cross Report/ 5 Line Cross Report (Evenly) **P15**
- ☐ Glossary of Terms **Back cover**

Report Elements at a Glance



Indicates scanning and/or clinical suggestion



Click pearl for Table of Contents

1 Report name

4 Image quality score

7 Capture date

2 OCT model name & version

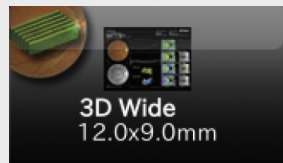5 Scan mode & parameters

8 Comment/signature/ date (recorded by writing on printout)

3 Patient information

6 Eye

3D Wide Report (12mm x 9mm)

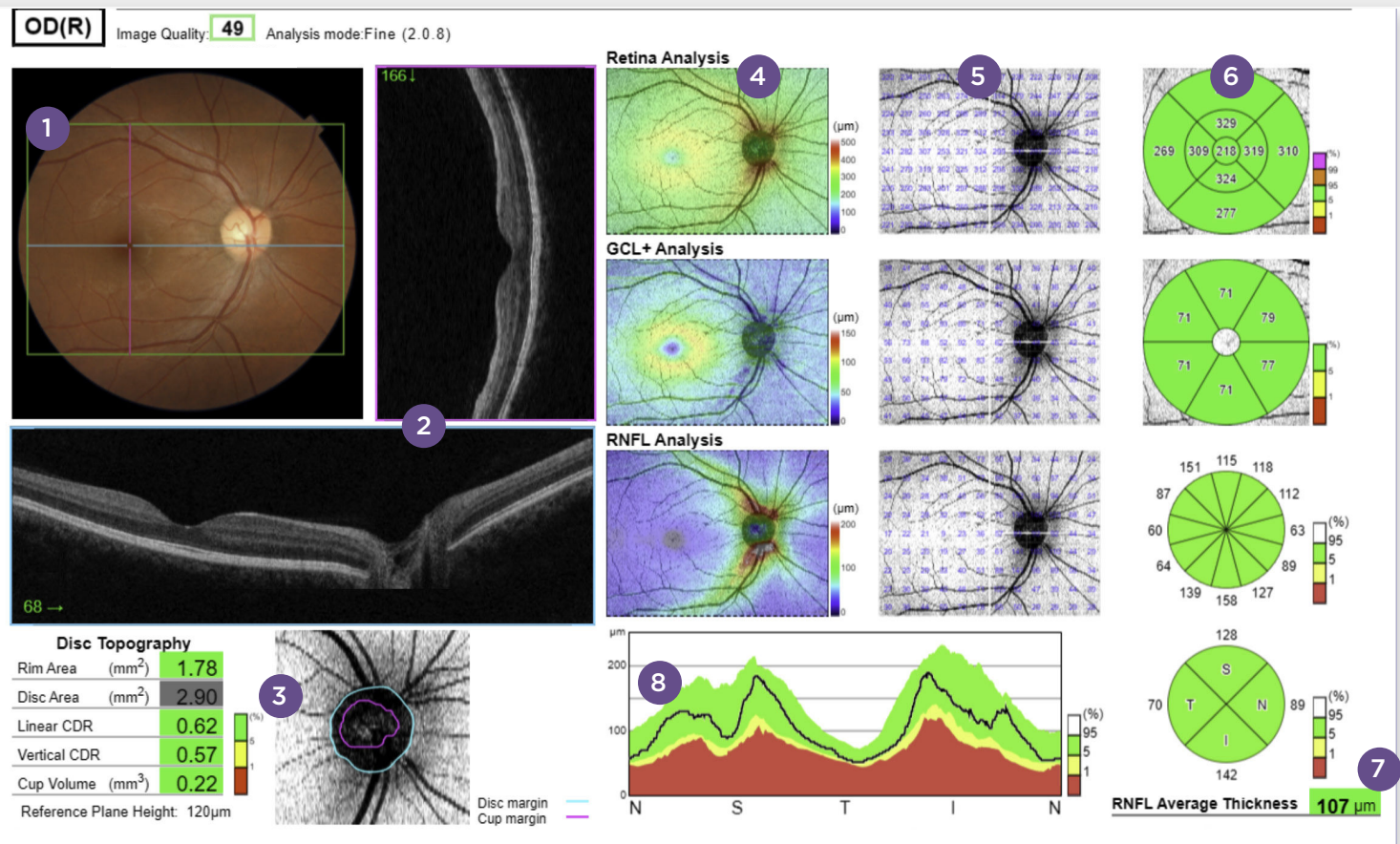


- Wide, 12x9 mm OCT report encompassing both the macula and optic nerve
- Includes 45° true-color fundus photograph, optic disc metrics and retinal/ganglion cell/RNFL thickness maps with reference data

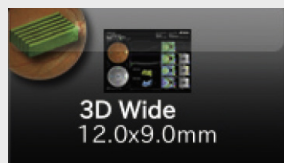

A comprehensive, go-to report generated from one wide OCT scan; ideal for “Wellness” use and beyond

- 1 True-color 45° fundus photograph with 12x9 mm OCT scan zone overlay with horizontal/vertical scan position
- 2 Horizontal /Vertical OCT scans; can be repositioned before printing
- 3 Disc topography with reference data; can be switched to 3D retinal layer segmentation surface images
- 4 Thickness maps with color scales; Retina, GCL+ or GCL++, RNFL
- 5 Thickness grids; Retina, GCL+ or GCL++, RNFL
- 6 Reference data; Retina /GCL+ or GCL++ /RNFL (clock hour and 4 sectors)
- 7 Average 3.4 mm cpRNFL thickness
- 8 cpRNFL 3.4 mm NSTIN thickness with reference data (TSNIT display option)



3D Wide Glaucoma Report

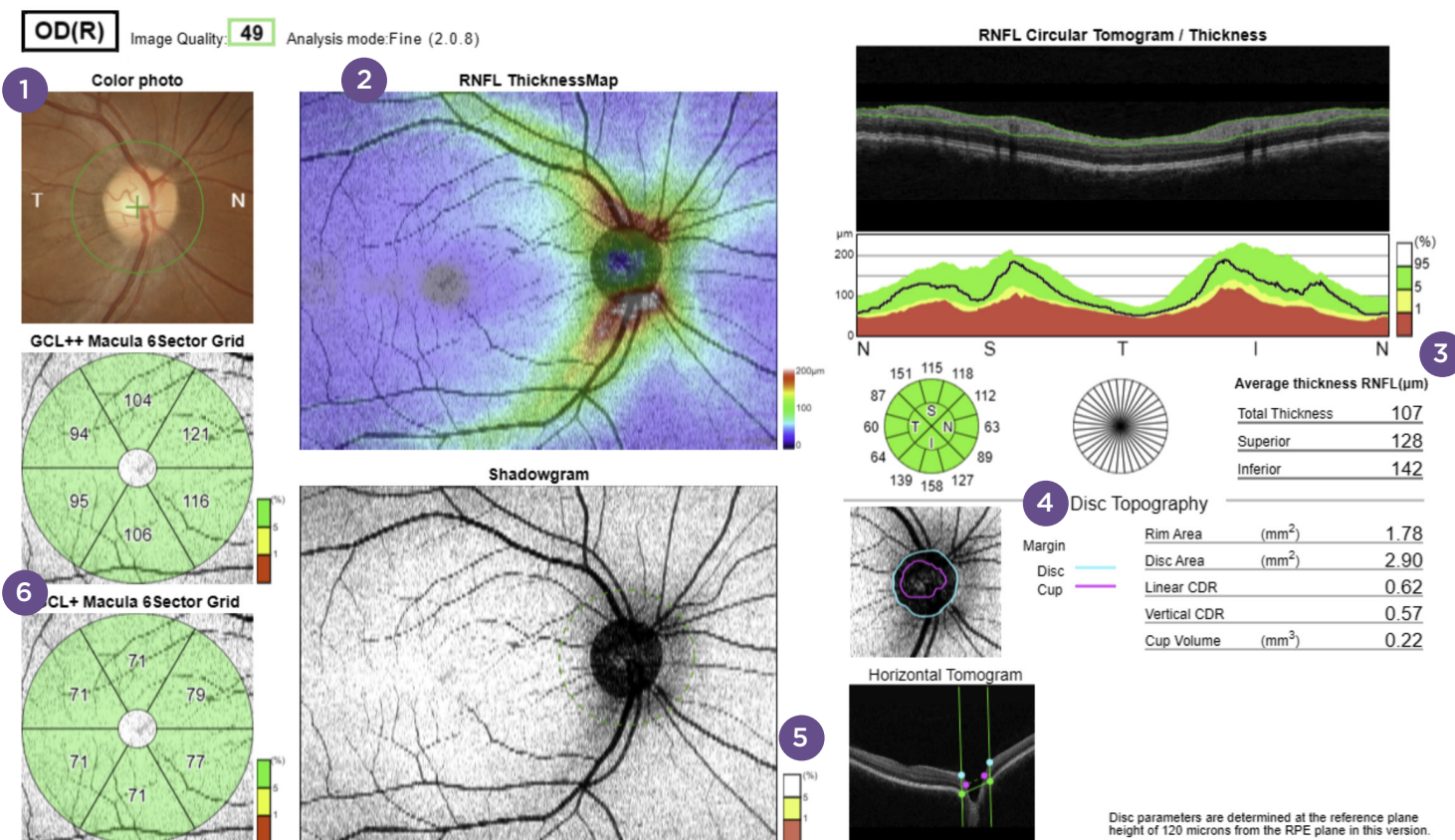


- Wide, 12x9 mm OCT scan report encompassing the macula and optic nerve
- 45° true-color fundus photograph magnified on the nerve, RNFL thickness, disc topography, GCL+ and GCL++ thickness with reference data



Used for a focused unilateral glaucoma assessment

- 1 True-color 45° fundus photograph magnified on the optic nerve with 3.4mm cpRNFL scan position
- 2 12x9 mm RNFL Thickness Map with color scale
- 3 3.4 mm cpRNFL tomogram, thickness and clock hour values with reference data
- 4 Disc Topography
- 5 12x9 mm OCT Shadowgram
- 6 GCL++ and GCL+ Macula 6 Sector Grid values with reference data

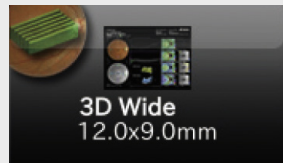

Click pearl for Table of Contents

3D Wide Glaucoma Report with Visual Field Test Points (Hood Report)



Scan/click here for a more comprehensive HOOD Report Guide

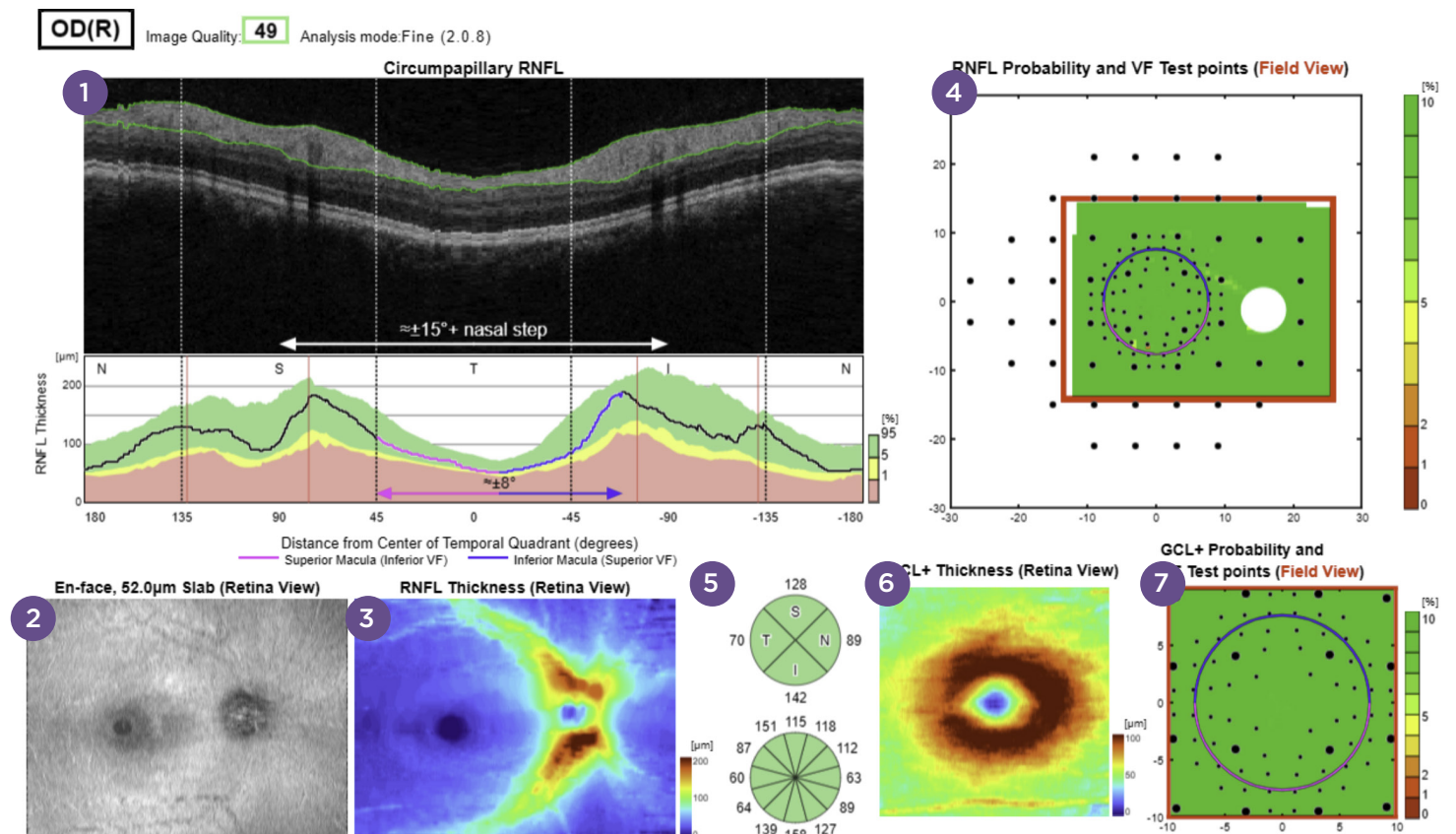


- One wide, 12x9mm OCT scan generates this novel report made to simplify and accelerate glaucoma diagnostic decision-making
- Helps visually correlate OCT structural findings to functional vulnerability*

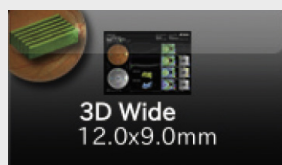

Used for glaucoma assessment

- 1 3.4 mm cpRNFL OCT scan enlarged with layer boundary lines, centered temporal sector and reference data
- 2 12x9 mm OCT En-face image
- 3 12x9 mm RNFL thickness map with vessel detail removed and color scale
- 4 Correlation of OCT RNFL thickness (Structure) with visual field test locations (Function)
- 5 3.4 mm cpRNFL thickness in 4 Sectors and 12 clock hours with reference data
- 6 GCL+ Thickness Map
- 7 Correlation of OCT GCL+ thickness (Structure) with visual field test locations (Function)

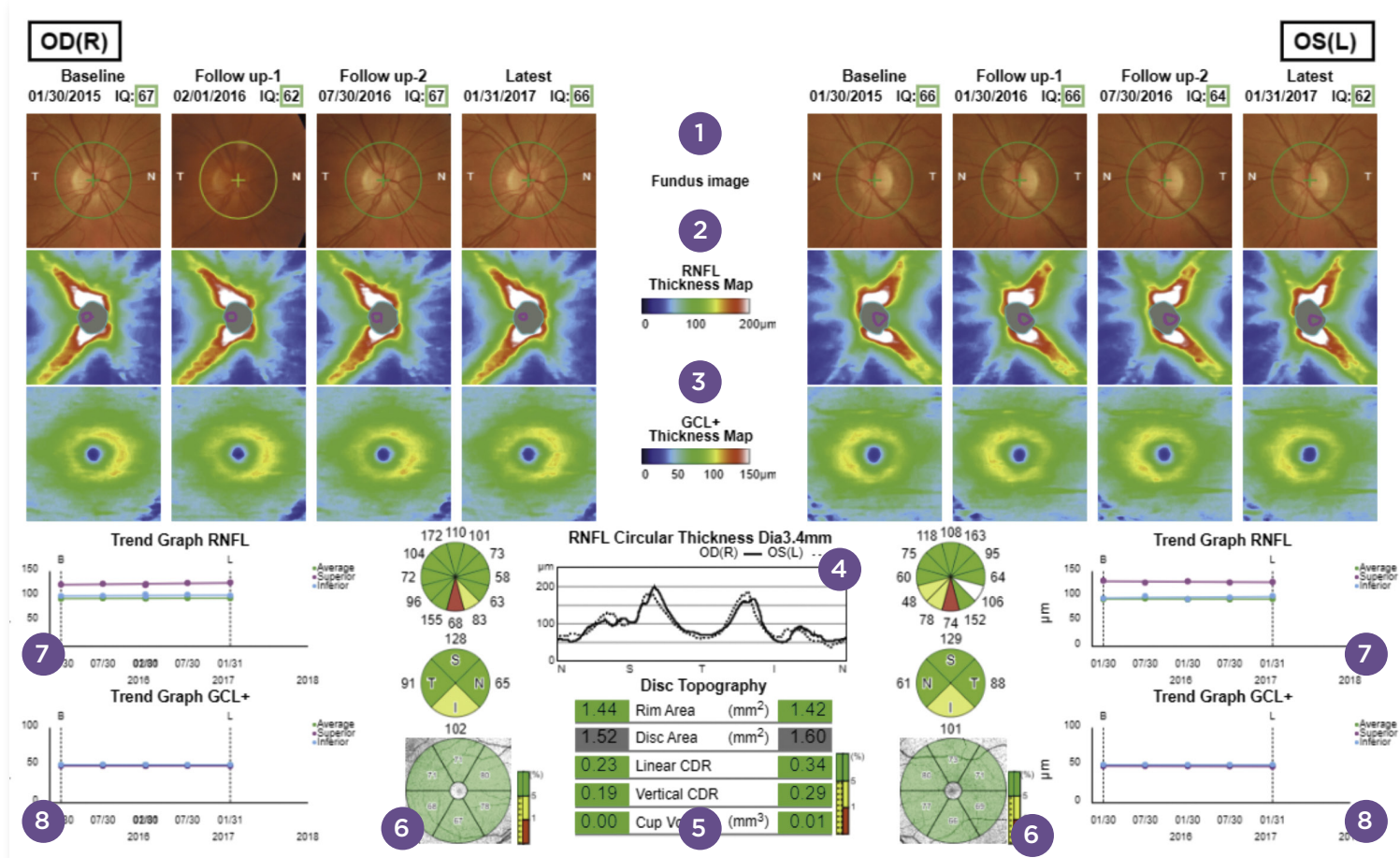


3D Wide Trend Analysis (OU)

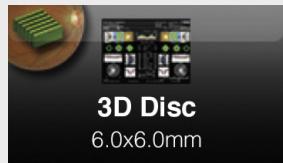


Comprehensive longitudinal assessment of optic nerve photographs, RNFL and ganglion cell thickness data in a change-over-time bilateral report

- 1 45° true-color fundus photographs magnified on optic nerve with cpRNFL scan position
- 2 RNFL Thickness Map with cup/disc margins and color scale
- 3 GCL+ Thickness Map with color scale
- 4 Latest visit 3.4 mm cpRNFL thickness NSTIN in 4 Sectors and 12 clock hours with reference data
- 5 Disc Topography with reference data, latest visit
- 6 GCL+ thickness with reference data, latest visit
- 7 Trend Graph cpRNFL
- 8 Trend Graph GCL+



3D Disc Report with Topography



Classic 6x6 mm OCT optic nerve scan offering conventional analyses with photography in a unilateral report



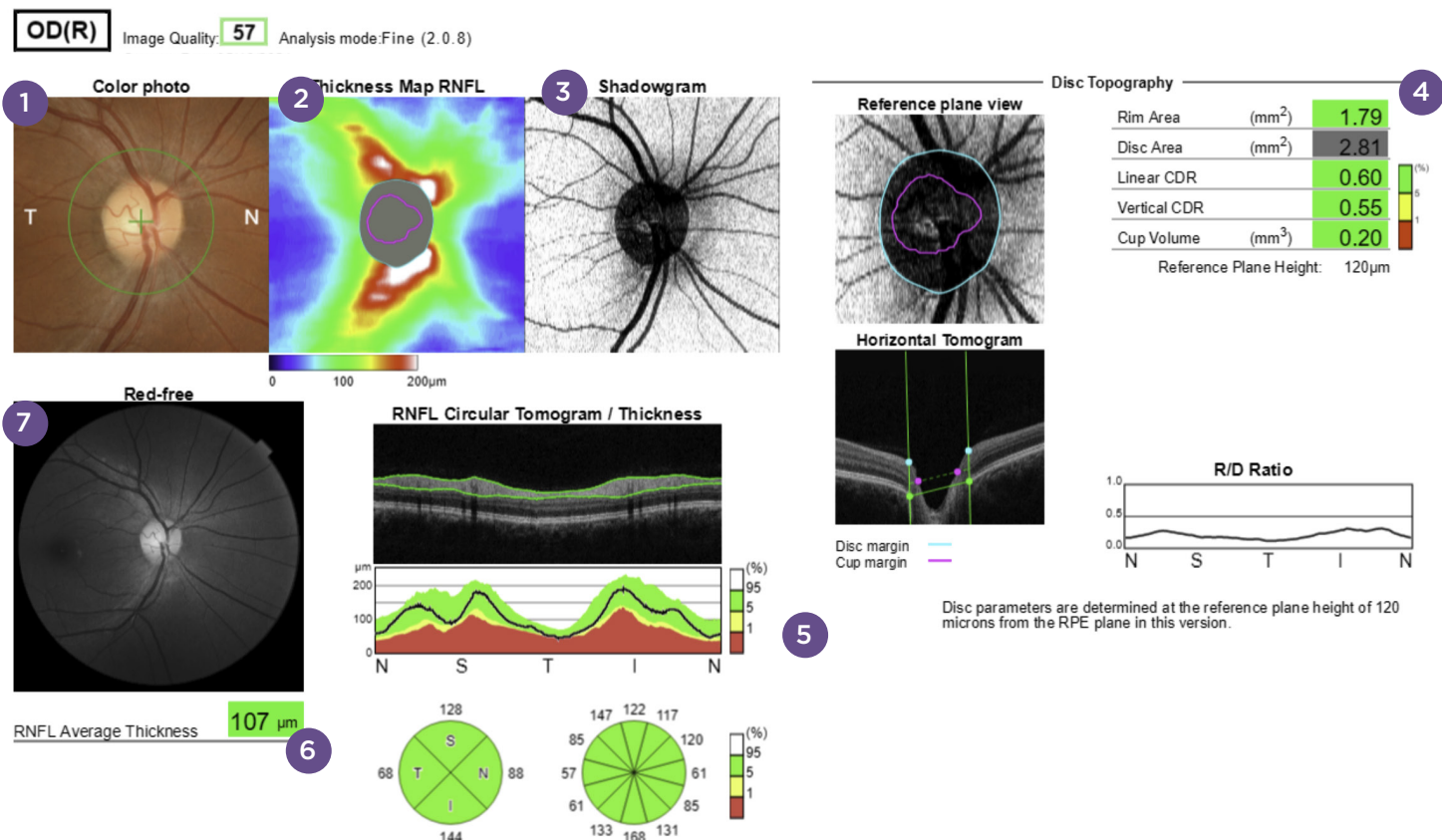
Rim Area: larger area = higher percentile

Linear CDR and Vertical CDR: smaller ratio = higher percentile

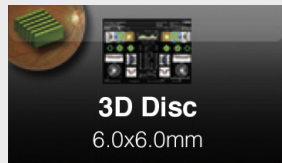
Cup Volume: smaller volume = higher percentile

Disc Area: no reference data for this parameter

- 1 True-color 45° fundus photograph magnified on the optic nerve with 3.4mm cpRNFL scan position.
- 2 6x6 mm RNFL thickness map with cup/disc margins and color scale
- 3 6x6 mm OCT Shadowgram
- 4 Disc Topography
- 5 3.4 mm cpRNFL Thickness (NSTIN) with reference data
- 6 3.4 mm cpRNFL average thickness
- 7 45° Red-free photograph



3D Disc Report (OU) with Topography



Classic optic nerve 6x6 mm OCT scans offering conventional analyses with photography in a bilateral report



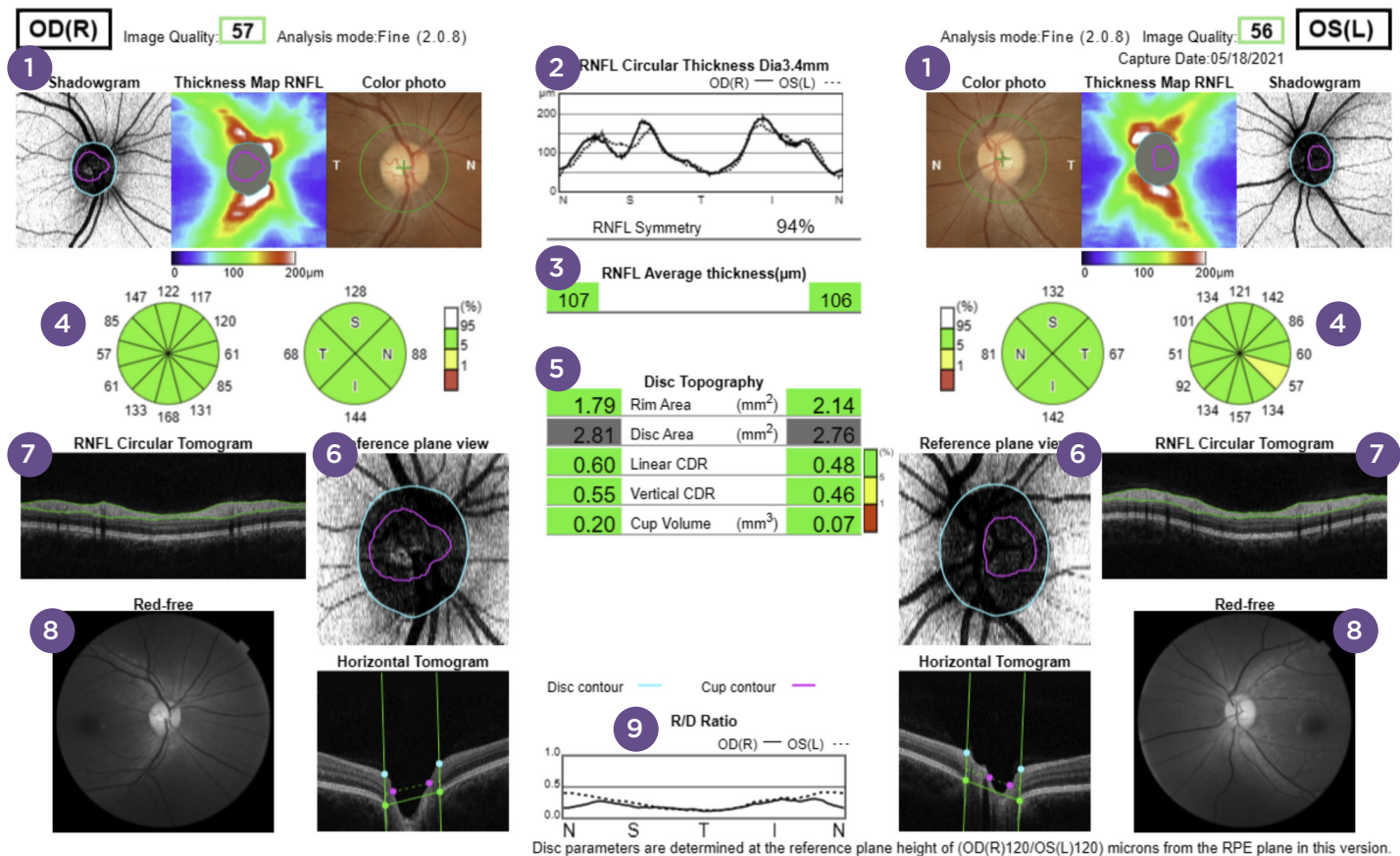
Rim Area: larger area = higher percentile

Linear CDR and Vertical CDR: smaller ratio = higher percentile

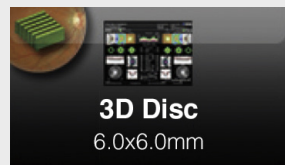
Cup Volume: smaller volume = higher percentile

Disc Area: no reference data for this parameter

- 1 OCT shadowgram with cup/disc margins, RNFL thickness map with color scale and cup/disc margins, true-color 45° fundus photograph magnified on the optic nerve with 3.4mm cpRNFL scan position
- 2 RNFL Circular Thickness Diameter 3.4mm presenting OD/OS thicknesses and symmetry percentage score
- 3 3.4mm cpRNFL average thickness OU
- 4 3.4mm cpRNFL thickness in 4 sectors and 12 clock hours with reference data
- 5 Disc Topography
- 6 Cup/Disc Reference Plane View
- 7 RNFL Circular Tomogram with layer boundary lines
- 8 45° Red-free photograph
- 9 Rim/Disc ratio

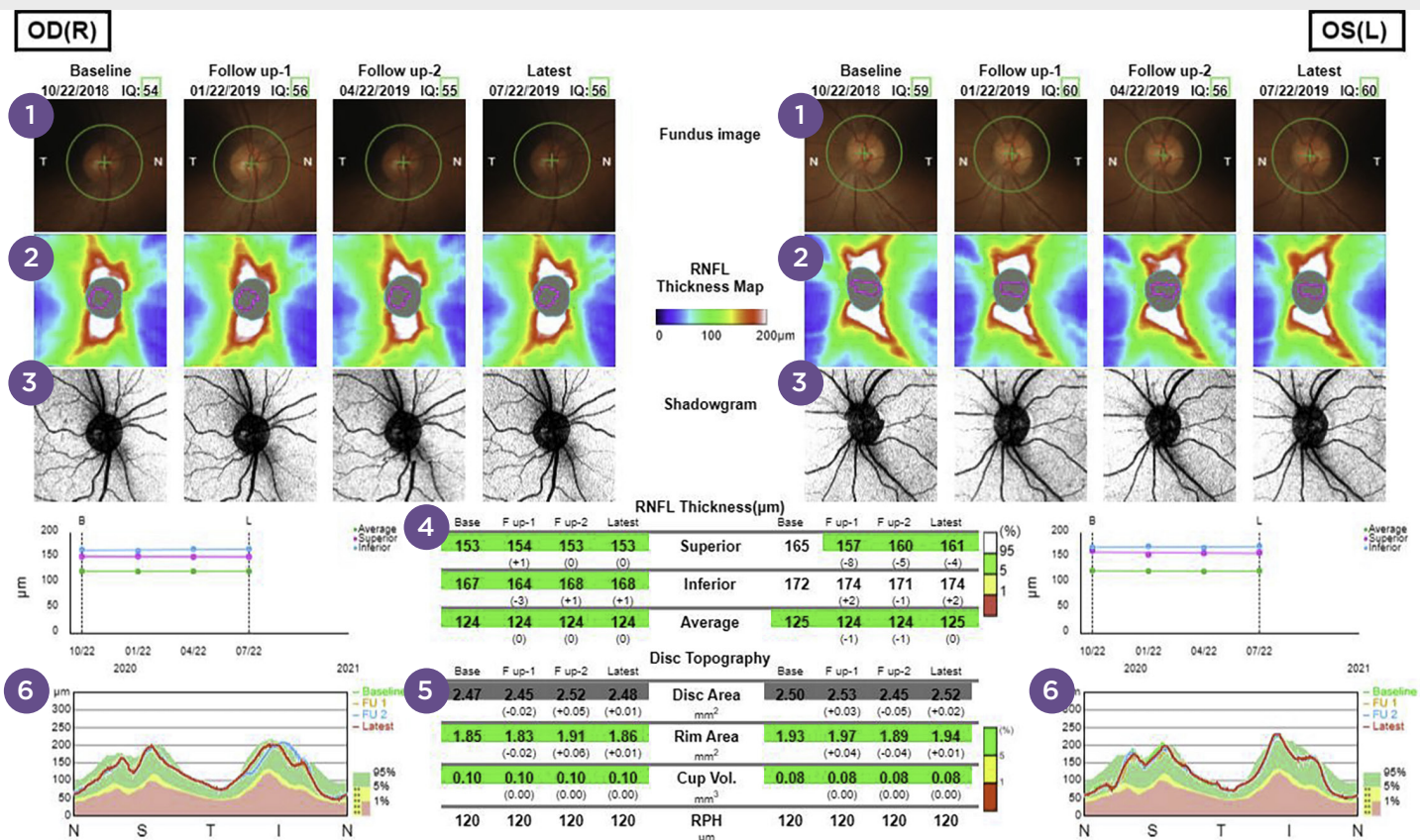


3D Disc Trend Analysis (OU)

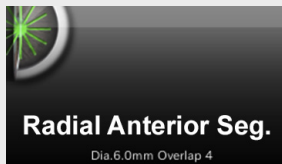

Classic longitudinal assessment of optic nerve photographs, RNFL and optic nerve data in a bilateral, change-over-time report

- 1 45° true-color fundus photographs magnified on optic nerve with cpRNFL scan position
- 2 6x6 mm RNFL Thickness Map with cup/disc margins and color scale
- 3 OCT Shadowgram
- 4 Average/Superior/Inferior cpRNFL thickness displayed in graph and table from baseline to latest
- 5 Disc Topography with reference data table displayed from baseline to latest visit
- 6 cpRNFL NSTIN thickness displayed in graph from baseline to latest

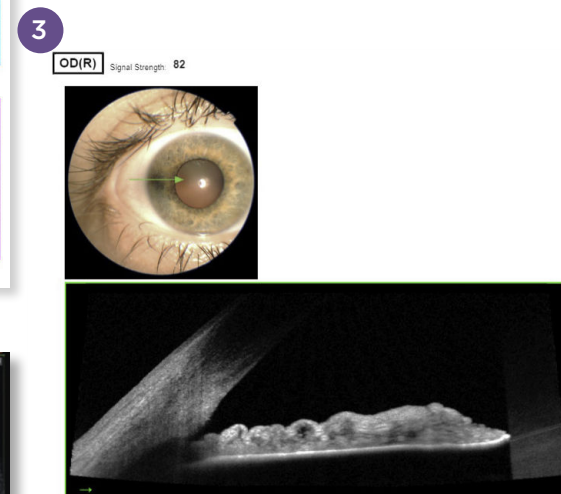
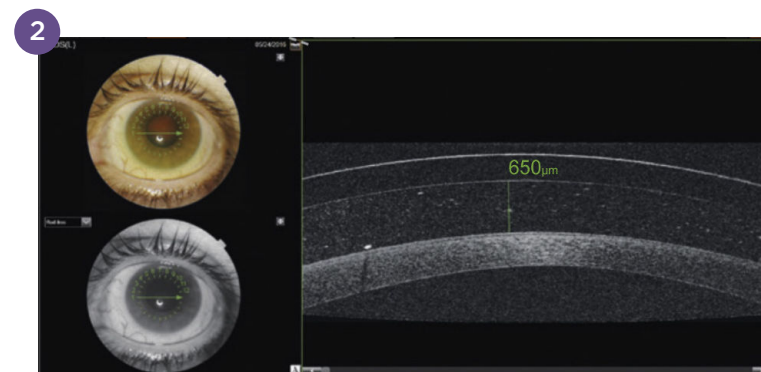
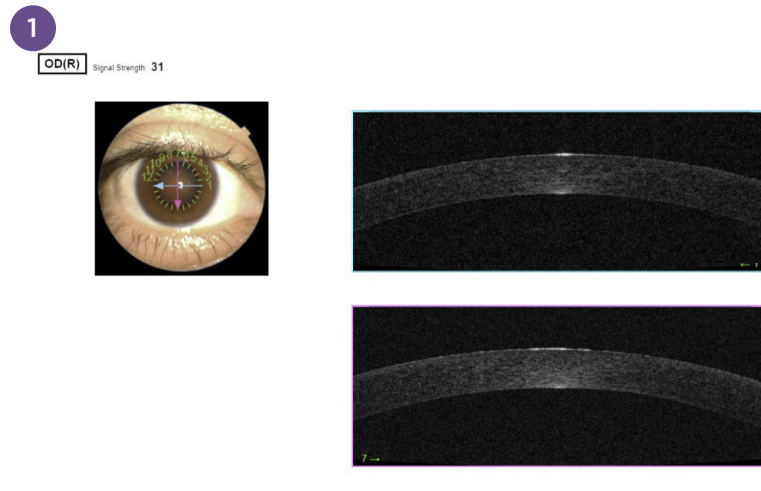


Anterior Segment



Simplified reports of powerful anterior segment OCT scans including the ability to display measurements

- 1 Anterior Radial Report (12 clock-hour scans of the cornea)
- 2 Anterior Radial (scleral lens with caliper tool measurement)
- 3 Anterior Line Report (angle)

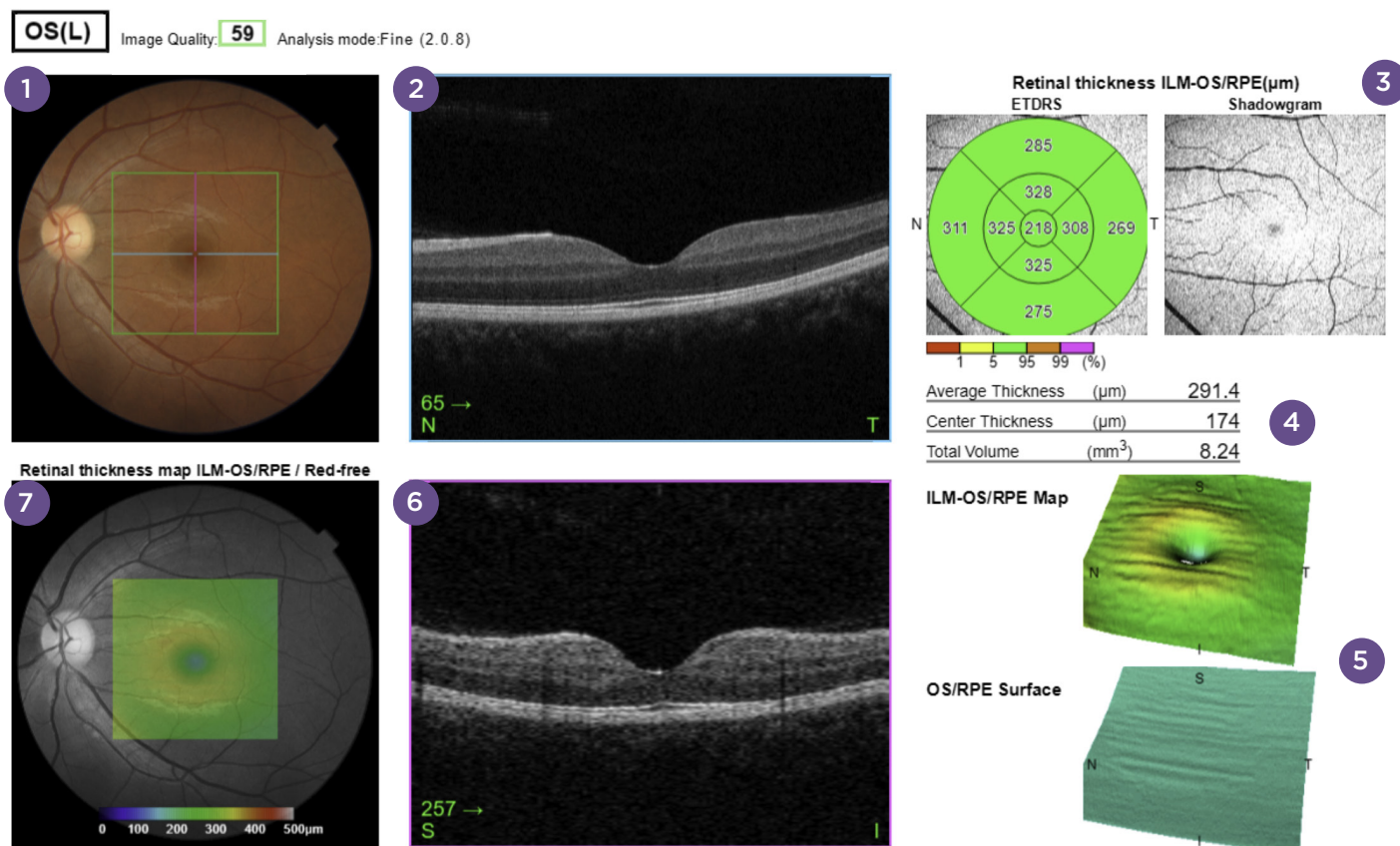


3D Macula Report



Classic 6x6 mm macular OCT scan report with conventional analyses and photography in a unilateral report

- 1 True-color 45° fundus photograph with horizontal (blue) and vertical (pink) scan position reference
- 2 Horizontal OCT scan (any horizontal scan can be selected for printing)
- 3 ETDRS thickness with reference data and OCT shadowgram
- 4 Average thickness, center thickness, and total volume
- 5 ILM-OS/RPE and OS/RPE three-dimensional layer segmentation maps
- 6 Vertical OCT scan (derived; any vertical scan can be selected for printing)
- 7 Red-free 45° fundus photograph with ILM-OS/RPE thickness overlay with color scale

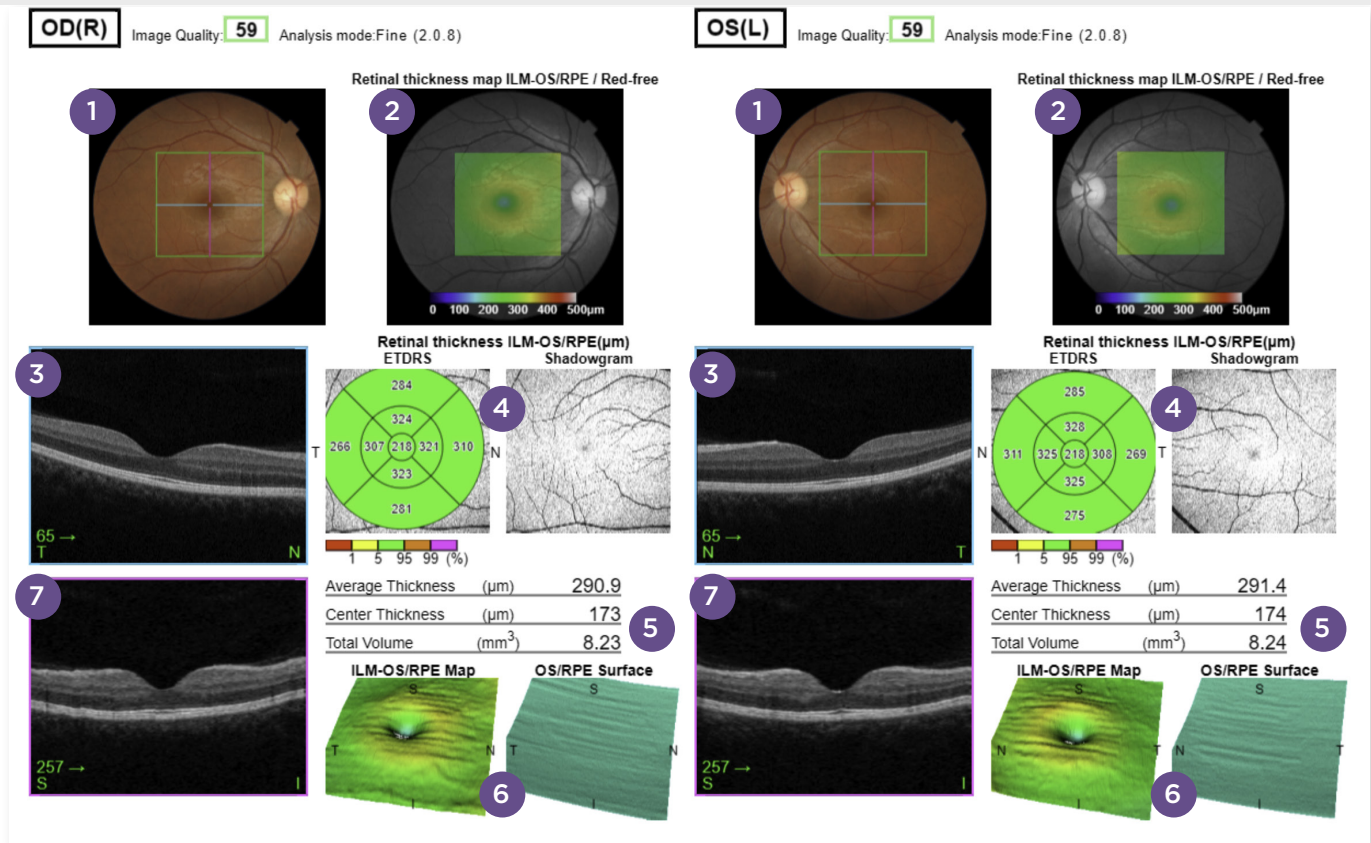


3D Macula Report (OU) Retina Analysis

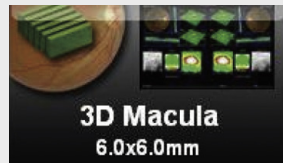

Classic 6x6 mm macular OCT scan report with conventional analyses and photography in a bilateral report

- 1 True-color 45° fundus photograph with horizontal (blue) and vertical (pink) scan positions
- 2 Red-free 45° fundus photograph with ILM-OS/RPE thickness overlay with color scale
- 3 Horizontal OCT scan
- 4 ETDRS thickness with reference data and OCT shadowgram
- 5 Average thickness, center thickness, and total volume
- 6 ILM-OS/RPE and OS/RPE three-dimensional layer segmentation maps
- 7 Vertical OCT scan (derived)



3D Macula Report (OU) GCL Analysis

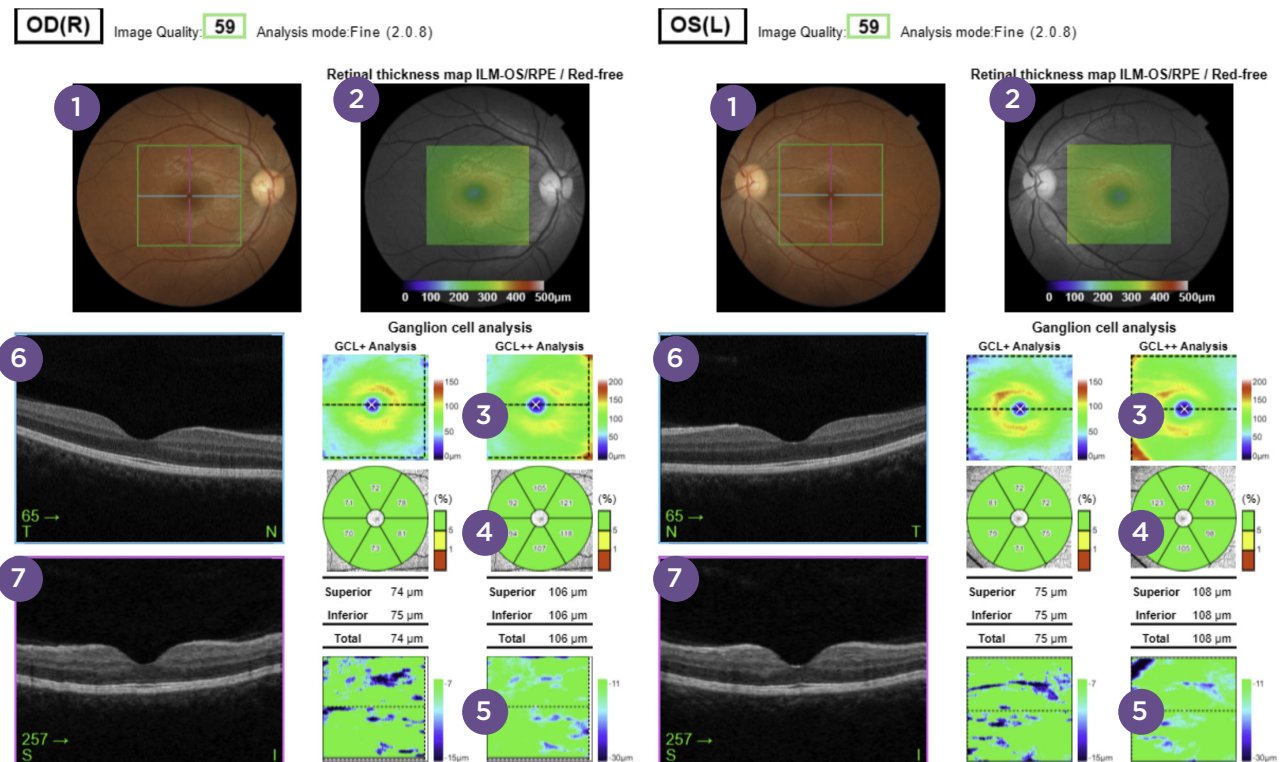


- Classic and powerful macular OCT bilateral scan report with emphasis on glaucoma analyses
- Includes true-color and red-free fundus photography with OCT thickness overlay, high-resolution OCT scans, both GCL+ and GCL++ thicknesses compared to reference data and superior/inferior thickness asymmetry maps

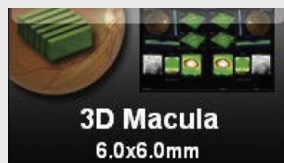

Complements the glaucoma patient traditionally scanned with 3D Disc

- 1 True-color 45° fundus photograph with horizontal (blue) and vertical (pink) scan positions
- 2 Red-free 45° fundus photograph with ILM-OS/RPE thickness overlay with color scale
- 3 GCL+, GCL++ thickness maps with color scale
- 4 GCL+, GCL++ and macula 6 sector grid values with reference data
- 5 Asymmetry thickness map between upper/lower GCL from the center line. Two points at line-symmetric are compared. Thinner is blue, equal is green.
- 6 Horizontal OCT scan
- 7 Vertical OCT scan (derived)



Compare Report Change Analysis

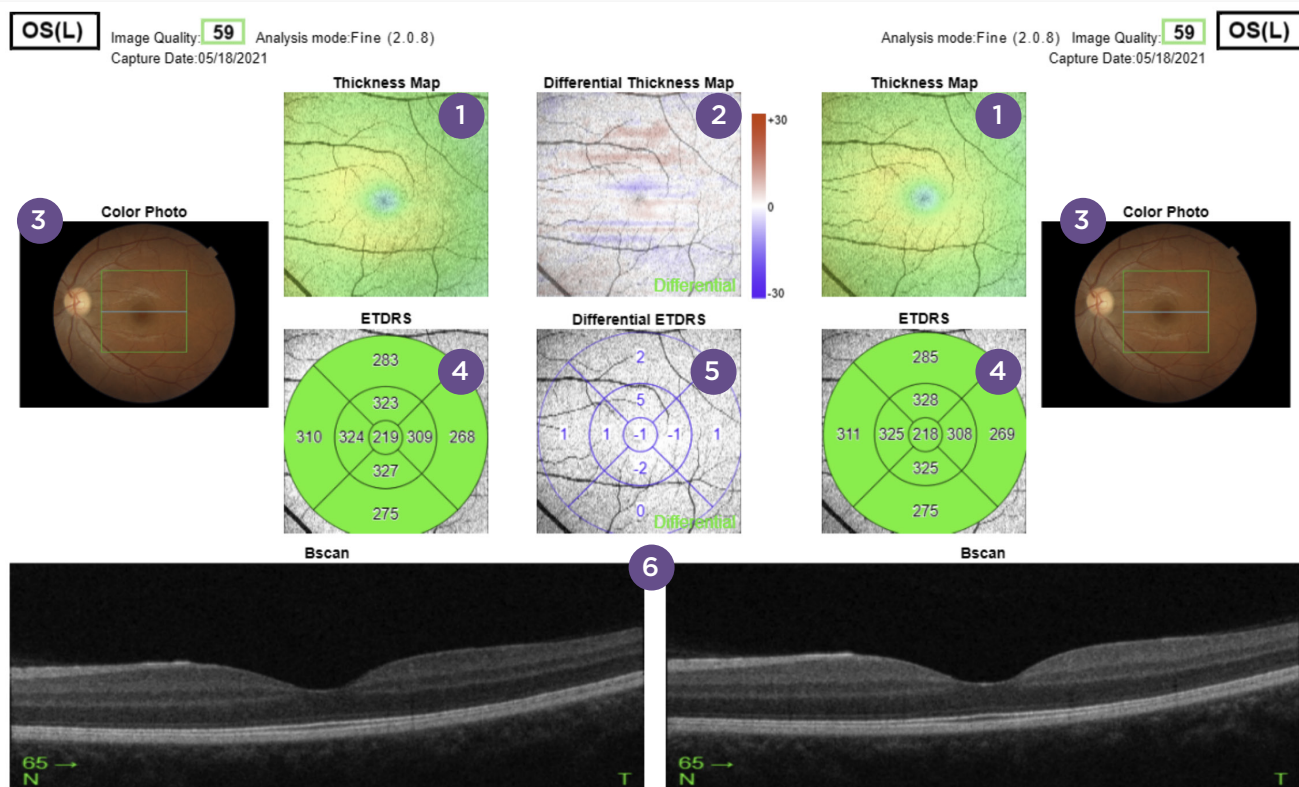


- Unilateral visit-to-visit change report with 45° true-color fundus photography, intersit-registered OCT scans (3D Macula or 3D Wide) and ETDRS thickness maps for each visit
- Includes color-coded Differential ETDRS Map and Differential ETDRS displaying thickness variance in +/- microns



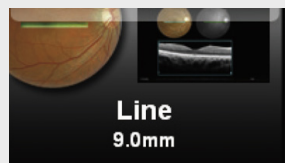
A report that may be used to assess visit-to-visit laser and/or intravitreal treatment outcomes

- 1 OCT Thickness Maps
- 2 OCT Differential Thickness Map with color scale
- 3 True-color 45° fundus photograph
- 4 ETDRS thickness
- 5 Differential ETDRS
- 6 Intersit-registered OCT B-scans



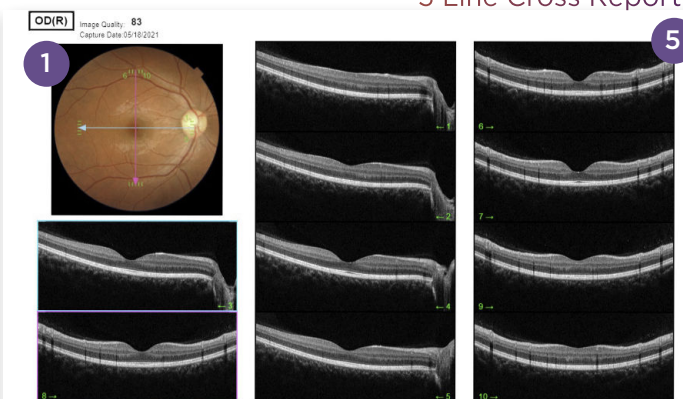
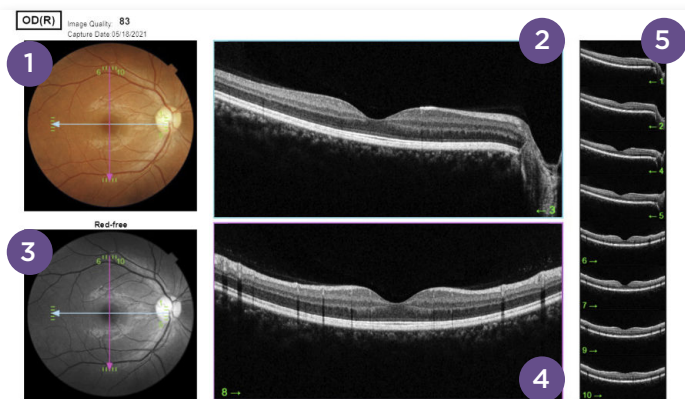
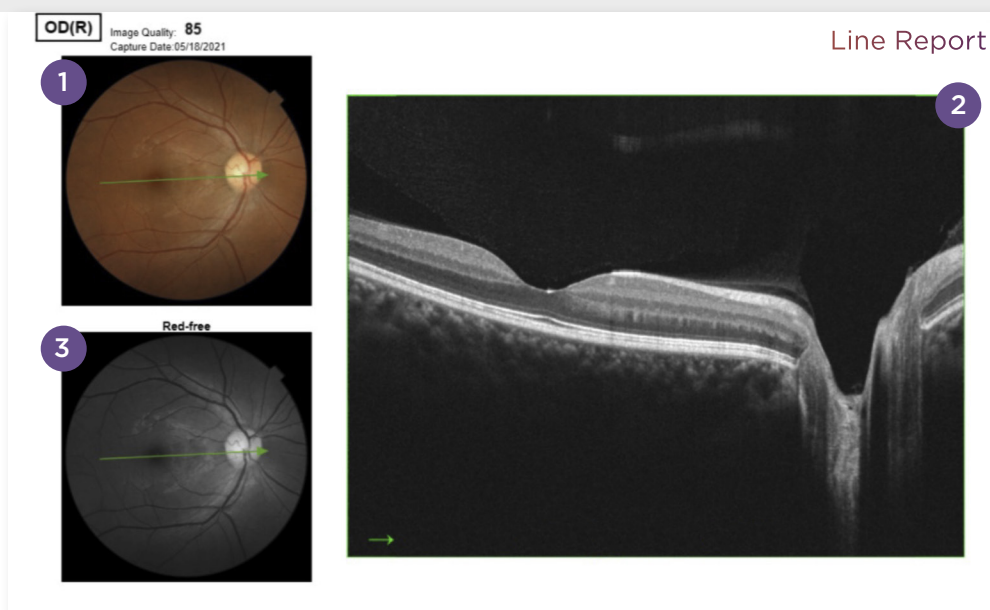
Click pearl for Table of Contents

Line Reports



- Line Report:** 45° color and red-free fundus photograph with highest resolution OCT scan
- 5 Line Cross Report:** 45° color and red-free fundus photographs with 5 horizontal and 5 vertical high resolution OCT scans with enlarged horizontal/vertical OCT Scans
- 5 Line Cross Report (Evenly):** 45° color fundus photograph with 5 horizontal and 5 vertical high resolution OCT scans shown equally sized

- 1 True-color 45° fundus photograph with scan position(s)
- 2 OCT scan (any horizontal 5 Line Cross scan can be selected for printing)
- 3 Red-free 45° fundus photograph with scan position(s)
- 4 Vertical OCT scan (any vertical 5 Line Cross scan can be selected for printing)
- 5 Equally sized OCT scans



LEARN MORE

Web: topconhealthcare.com

Contact Sales: 1.844.9TOPCON

Topcon Healthcare University

Eye Health Education Begins Here:

learning.topcon.com

or scan/click here



GLOSSARY OF TERMS

cpRNFL	(Circumpapillary Retinal Nerve Fiber Layer)
CDR	(Cup-to-Disc Ratio)
ETDRS	(Early Treatment Diabetic Retinopathy Study)
GCL	(Ganglion Cell Layer)
GCL+	(GCL and IPL Layers)
GCL++	(RNFL, GCL and IPL Layers)
IPL	(Inner Plexiform Layer)
NSTIN	(Nasal-Superior-Temporal-Inferior-Nasal)
OCT	(Optical Coherence Tomography)
OD	(Right Eye)
OS	(Left Eye)
OU	(Both Eyes)
RNFL	(Retinal Nerve Fiber Layer)
RPE	(Retinal Pigment Epithelium)
TSNIT	(Temporal-Superior-Nasal-Inferior-Temporal)

*All OCT reports in this guide can be generated on Topcon Maestro OCTs with IMAGEnet 6 software.
Report data shown is for representation purposes only.